

The Effects of Early Preorthodontic Trainer Treatment on Class II, Division 1 Patients

Serdar Usumez, DDS, PhD^a; Tancan Uysal, DDS, PhD^b; Zafer Sari, DDS, PhD^a;
Faruk Ayhan Basciftci, DDS, MS^a; Ali Ihya Karaman, DDS, MS, PhD^c;
Enis Guray, DDS, PhD^d

Abstract: The aim of this study was to clarify the dentoskeletal treatment effects induced by a preorthodontic trainer appliance treatment on Class II, division 1 cases. Twenty patients (10 girls and 10 boys, mean age 9.6 ± 1.3 years) with a Class II, division 1 malocclusion were treated with preorthodontic trainer appliances (Myofunctional Research Co., Queensland, Australia). The patients were instructed to use the trainer every day for one hour and overnight while they slept. A control group of 20 patients (mean age 10.2 ± 0.8 years) with untreated Class II, division 1 malocclusions was used to eliminate possible growth effects. Lateral cephalograms were taken at the start and end of treatment. Final cephalograms were taken 13.1 ± 1.8 months after trainer application, compared with a mean of 11.2 ± 2.4 months later for the control group. The mean and standard deviations for cephalometric measurements were analyzed by paired-samples *t*-test and independent-samples *t*-tests. At the end of the study period, the trainer group subjects showed significant changes including anterior rotation and sagittal growth of the mandible, increased SNB and facial height, reduced ANB, increased lower incisor proclination, retroclination of upper incisors, and overjet reduction. However, only total facial height increase, lower incisor proclination, and overjet reduction were significantly higher when compared with the changes observed in the control group. This study demonstrates that the preorthodontic trainer application induces basically dentoalveolar changes that result in significant reduction of overjet and can be used with appropriate patient selection. (*Angle Orthod* 2004; 74:605–609.)

Key Words: Myofunctional treatment; Preorthodontic trainer; Class II, division 1

INTRODUCTION

Much attention has been paid to the problem of controlling dentofacial growth interferences caused by abnormal lip and tongue function in the mixed dentition period. Various appliances have been presented for the treatment of this problem.¹⁻⁷ The main purpose of these appliances has been to eliminate oral dysfunction, establish muscular balance, and correct or diminish maxillary incisor protrusion.⁸

Excessive dental protrusion and excessive overjet are characteristics of these cases, particularly in connection with thumb or lip sucking and tongue thrusting.⁸ McNamara⁹ claimed that the most frequent skeletal problem in Class II malocclusions in preadolescents is mandibular retrognathia. This suggests that an appliance with the demonstrated ability to stimulate significant mandibular growth would be an important part of the clinician's armamentarium. Animal studies have shown that appliances that position the mandible anteriorly can stimulate significant mandibular growth, primarily by an enhanced remodeling response at the condyle.¹⁰⁻¹³

Myofunctional appliances have been used for many years. There is a definite place for these appliances in orthodontics today because they are simple and economical, but the cases need to be carefully selected, and the operator needs to be well trained in their use.

Class II, division 1 malocclusions may be treated effectively in actively growing patients with any type of functional appliance.^{13,14} The principal aims of dentofacial orthopedic treatment of skeletal Class II, division 1 malocclusions with an activator are to correct the dental arch

^a Assistant Professor, Department of Orthodontics, School of Dentistry, Selcuk University, Konya, Turkey.

^b Research Assistant, Department of Orthodontics, School of Dentistry, Selcuk University, Konya, Turkey.

^c Associate Professor and Head, Department of Orthodontics, School of Dentistry, Selcuk University, Konya, Turkey.

^d Associate Professor, Department of Orthodontics, School of Dentistry, Selcuk University, Konya, Turkey.

Corresponding author: Tancan Uysal, DDS, Orthodontics, Selcuk Universitesi Dis Hekimligi Fakultesi, Ortodonti A. D., Konya 42079, Turkey

(e-mail: tancanuysal@selcuk.edu.tr).

Accepted: October 2003. Submitted: September 2003.

© 2004 by The EH Angle Education and Research Foundation, Inc.

TABLE 1. Intra- and Intergroup Values and Their Comparisons for the Control and Test Groups. Skeletal and Dental Measurements of the Pre- and Posttreatment and Pre- and Postcontrol Lateral Cephalograms

		Trainer Group (n = 20)						P-Value Paired-Samples t-Test
		Pretreatment, 0 mo		Posttreatment, 13.1 ± 1.8 mo		Difference		
		Mean	SD	Mean	SD	Mean	SD	
1	SNA (°)	79.51	2.81	79.64	3.34	0.13	1.02	NS ^a
2	SNB (°)	73.80	1.83	75.12	2.55	1.31	1.35	.001**
3	ANB (°)	5.71	1.58	4.52	2.03	-1.19	1.18	.001**
4	Sn-GoGn (°)	35.81	5.32	34.28	5.44	-1.50	1.76	.003**
5	FH-MP (°)	26.97	4.93	25.44	5.54	-1.53	2.35	.020*
6	PP-MP (°)	27.56	5.99	26.41	6.12	-1.16	2.28	NS
7	Gn-Go-Ar (°)	127.50	6.45	127.18	6.67	-0.31	3.11	NS
8	Ar-S-N (°)	124.19	6.19	124.41	6.52	0.22	3.65	NS
9	Me-Go-S (°)	115.06	5.50	114.00	6.16	-1.06	5.99	NS
10	OP-SN (°)	21.25	3.40	20.00	4.35	-1.25	2.11	.032*
11	MaxP Angle (°)	4.62	2.33	4.09	1.88	-0.53	2.08	NS
12	Ramus height (mm)	57.06	4.31	58.06	2.86	1.00	3.22	NS
13	Corpus length (mm)	64.69	4.39	65.69	4.11	1.00	2.39	NS
14	N-Me (mm)	111.69	5.24	114.37	5.10	2.69	2.06	.000***
15	S-Go (mm)	70.78	4.73	72.75	4.95	1.97	2.15	.002**
16	Go-Ar (mm)	42.25	3.86	43.12	3.34	0.91	2.22	NS
17	Go-Me (mm)	63.75	5.67	65.31	4.80	1.56	3.39	NS
18	Co-Gn (mm)	103.69	5.91	106.56	5.25	2.88	4.53	.023*
19	Co-A (mm)	85.69	5.02	86.88	4.15	1.19	3.85	NS
20	Go-PC (mm)	50.56	5.54	50.81	5.54	0.25	4.06	NS
21	U1-NA (mm)	3.78	2.18	3.31	2.85	-0.50	1.76	NS
22	U1-NA (°)	24.56	6.97	22.62	6.38	-1.97	6.05	NS
23	U1-SN (°)	104.00	6.81	100.38	6.56	-3.63	5.19	.014*
24	L1-NB (mm)	5.04	2.23	6.06	2.38	0.99	1.64	.025*
25	L1-NB (°)	27.69	4.24	30.44	5.33	2.75	3.89	.013*
26	IMPA (°)	95.94	6.25	99.56	7.34	3.63	3.86	.002**
27	Interincisal angle	122.81	9.12	123.13	7.83	0.31	6.37	NS
28	Overjet (mm)	6.83	1.65	3.16	1.67	-3.75	1.60	.000***
29	Overbite (mm)	2.12	2.73	1.94	2.12	-0.22	1.76	NS

^a NS, not significant.

* $P < .05$.

** $P < .01$.

*** $P < .001$.

relationship and to improve the patient's facial profile by promoting favorable mandibular growth changes.^{13,15}

Bergersen¹⁶ stated that excessive overjet ideally should be corrected before full eruption of the permanent incisors so that the lingual surfaces of the upper incisors will provide stops to prevent increases in overbite. However, two mm of overjet should remain after correction to ensure that continued mandibular growth does not lead to prognathism.¹⁶

Tulloch et al¹⁷ identified 50 studies conducted between 1980 and 1987 that reported the treatment of young patients with Class II malocclusion. Because of the various inherent limitations of the different investigations, they were unable to determine whether orthodontic treatment significantly influenced the growth potential of Class II patients.

Woodside et al¹⁸ indicated that mandibular growth is achieved by changes in the mode of breathing and that passive maxillary expansion plus bite opening was achieved

by changes in tongue position. Linder-Aronson et al¹⁹ claimed that a child passing from oral to nasal breathing increases the horizontal growth of the mandible and normalizes incisor position.

To initiate Class II orthopedic therapy at an earlier age and to correct functional problems of soft tissues such as lingual malposition, the centripetal thrust of the lips and cheeks, oral respiration, and bruxism need to be part of the goal. With this aim, our attention was drawn to the preorthodontic trainer (Figure 1), a functional device usable in children from the age of four to 10 years. Quadrelli et al²⁰⁻²² recommended this appliance to correct the interposition of lips between dental arches, atypical swallowing, and the centripetal thrust of cheeks upon the dental arches; to discourage oral respiration; to avoid bruxism; and to favor the action of the external pterygoid and thus encourage the active push of the mandible.

The trainer and similar appliances are claimed to en-

TABLE 1. Extended

Control Group (n = 20)						P-Value	
First Observation, 0 mo		Second Observation, 11.2 ± 2.4 mo		Difference		Paired-Samples t-Test	Independent- Samples t-Test
Mean	SD	Mean	SD	Mean	SD		
80.46	3.06	80.35	3.11	-0.11	1.70	NS	NS
74.58	3.08	74.99	3.36	0.41	1.64	NS	NS
5.86	1.40	5.36	1.51	-0.50	1.24	NS	NS
35.63	5.85	35.29	6.09	-0.34	1.90	NS	NS
26.44	5.04	26.25	5.73	-0.20	3.19	NS	NS
28.63	5.81	28.06	5.87	-0.57	2.40	NS	NS
124.34	5.80	124.62	6.60	0.29	2.12	NS	NS
128.36	4.23	127.84	4.84	-0.52	2.65	NS	NS
108.62	5.76	108.92	5.82	0.31	1.32	NS	NS
16.98	4.76	16.49	4.77	-0.49	1.57	NS	NS
-2.20	2.73	-1.83	2.87	0.38	2.88	NS	NS
60.76	5.24	61.51	4.88	0.75	2.54	NS	NS
65.14	3.78	65.57	3.33	0.43	0.99	NS	NS
117.15	7.41	117.67	7.39	0.50	0.31	.004**	.000***
75.64	5.07	76.68	4.91	1.04	0.63	.000***	NS
45.62	2.94	46.52	3.15	0.90	1.59	.020*	NS
67.86	4.16	68.74	3.92	0.88	1.57	.022*	NS
109.55	6.15	111.01	6.27	1.47	2.60	.021*	NS
85.02	3.70	85.47	4.21	0.45	2.48	NS	NS
50.26	3.43	50.80	3.55	0.54	1.69	NS	NS
5.70	2.25	5.90	2.47	0.20	1.40	NS	NS
22.65	7.41	24.00	7.53	1.35	3.87	NS	NS
78.00	7.20	7.10	6.73	-0.90	3.09	NS	NS
5.15	1.90	5.00	1.97	-0.15	1.56	NS	.040*
24.70	5.50	24.40	5.74	-0.30	3.74	NS	.023*
94.65	5.71	94.20	6.51	-0.45	4.36	NS	.006**
126.75	9.29	126.25	8.10	-0.50	5.41	NS	NS
8.47	3.52	8.33	3.12	-0.13	0.78	NS	.000***
3.05	2.00	3.11	2.07	0.06	0.39	NS	NS

courage transverse bone growth by acting as a “shield” for the cheeks and bringing about muscular relaxation and protection of the teeth and articulations from bruxism, by virtue of the “bite effect.”^{23,24} The trainer is claimed to correct a skeletal Class II by an active mandibular force. By distancing the lower lips from the dental alveolar arch, the trainer is claimed to prevent a malposition of the tongue and lower lip during swallowing, thus solving the associated dental open bite. It is also reported to promote nasal respiration.²⁵

Therefore, this study cephalometrically evaluates the overall changes that occur during treatment with a preorthodontic trainer appliance and compares these changes with an untreated Class II, division 1 control group.

MATERIALS AND METHODS

The study included 40 children with skeletal Class II, division 1 malocclusions. Ten male and 10 female patients, treated between 2000 and 2002, were selected as the treatment group. The ANB angles of all patients were greater than four degrees, and their overjets were greater than 4.5

mm. None of the children in the test or control group had a thumb-sucking habit. All were Caucasian, and their ages ranged from 8.3 to 10.9 years (9.6 ± 1.3 years). All were treated exclusively with the preorthodontic trainer appliance (Myofunctional Research Co., Queensland, Australia). The patients were instructed to use the trainer every day for one hour and overnight while they slept.

The remaining samples formed the untreated control group to eliminate possible growth effects. This group consisted of 10 boys and 10 girls, with similar Class II, division 1 malocclusions ($ANB > 4^\circ$, and an overjet greater than five mm). All were Caucasian with ages ranging from 9.6 to 11.0 years (10.2 ± 0.8 years). The subjects in the control group were informed about orthodontic treatment but refused treatment.

Lateral cephalograms were taken at the start and end of treatment. Final cephalograms were taken after 13.1 ± 1.8 months of trainer application and 11.2 ± 2.4 months of growth in the control group. The radiographs were traced and measured by two investigators (Dr Usumez and Dr Uysal). The landmarks were located according to the definition provided by Başçiftçi et al.¹³

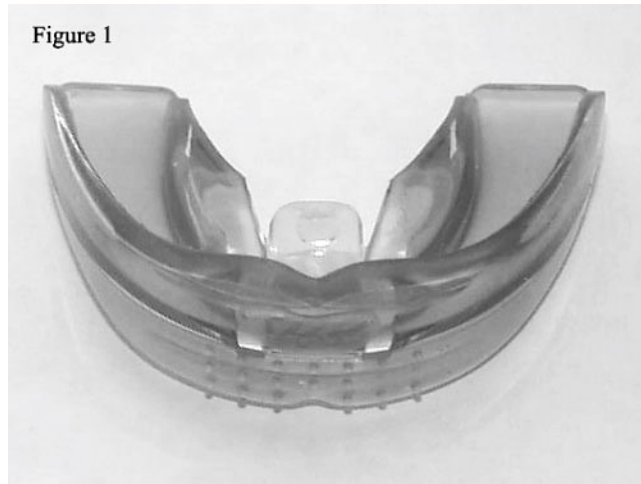


FIGURE 1. The preorthodontic trainer appliance.

All statistical analyses were performed using the SPSS software package (SPSS for Windows, version 10.0.1, SPSS Inc, Chicago, Ill). The mean differences between the pretreatment and posttreatment measurements and the first and second observation period measurements for the control group were evaluated using the paired *t*-test. Student's *t*-test was applied for comparison of the groups.

Two weeks after the first measurements, 30 radiographs were selected at random and retraced. A paired-samples *t*-test was applied to the first and second measurements. It was found that the difference between the first and second measurements of the 30 radiographs was insignificant. Correlation analysis applied to the same measurements showed that the highest *r* value was 0.99 for the interincisal angle and the lowest *r* value 0.91 for FH-MP.²⁶

RESULTS

The data from skeletal and dental measurements of the pre- and posttreatment and pre- and postcontrol lateral cephalograms are summarized in Table 1.

Pre- and posttreatment skeletal differences

Preorthodontic trainer group. In group I, treatment was associated with increases in the mean values for N-Me (2.69 ± 2.06) ($P > .001$), SNB (1.31 ± 1.35), S-Go (1.97 ± 2.15) ($P > .01$), and Co-Gn (2.88 ± 4.53) ($P > .05$). In group I, treatment also was associated with decreases in ANB (-1.19 ± 1.18), SN-GoGn (-1.50 ± 1.76) ($P > .01$), FH-MP (-1.53 ± 2.35), and OP-SN (-1.25 ± 2.11) ($P > .05$) (Table 1).

Control group. In the control group, the means increased for S-Go (1.04 ± 0.63) ($P > .001$), N-Me (0.50 ± 0.31) ($P > .01$), Go-Ar (0.90 ± 1.59), Go-Me (0.88 ± 1.57), and Go-Me (1.47 ± 2.60) ($P > .05$) (Table 1).

Intergroup comparisons. The mean differences in the study group were compared with the mean differences in

control group using the Student's *t*-test for unpaired samples. The mean difference of the study group was larger than that of the control group for only facial height, N-Me (mm), ($P > .001$).

Pre- and posttreatment dental differences

Preorthodontic trainer group. In group I, treatment resulted in decreases in U1-SN (deg) (-3.63 ± 5.19) ($P > .05$) and overjet (mm) (-3.75 ± 1.60) ($P > .001$). The means increased with treatment for L1-NB (mm) (0.99 ± 1.64), L1-NB (deg) (2.75 ± 3.89) ($P > .05$), and IMPA (3.63 ± 3.86) ($P > .01$).

Control group. No statistically significant differences were observed between the first and second measurements of the control group.

Intergroup comparisons. The mean differences were significantly decreased more in the study group than in the control group for U1-SN (deg) and L1-NB ($P > .05$), IMPA ($P > .01$), and overjet (mm) ($P > .001$) (Table 1).

DISCUSSION

This study of a sample of 40 children with Class II, division 1 malocclusion was designed to study the effect of treatment with the preorthodontic trainer appliance. The observed changes during treatment reflect the combined effects of treatment and individual growth. Ideally, a matched or at least comparable control group should be included for identifying the changes due to growth.^{13,14,27-29} Therefore, a control group consisting of longitudinal growth data for untreated Class II, division 1 malocclusion subjects was used in this investigation to eliminate possible differences in growth pattern.

It was decided to initiate Class II orthopedic therapy at an earlier age to correct functional problems in the soft tissues such as lingual malposition, the centripetal thrust of lips and cheeks, oral respiration, and bruxism. A functional device, the preorthodontic trainer appliance (Figure 1), was used in this study for this purpose. Quadrelli et al²⁰⁻²² indicated that the trainer appliance can be used for children four to 10 years old and recommended it to correct the interposition of lips between dental arches, atypical swallowing, and centripetal thrust of cheeks upon the dental arches; to discourage oral respiration; to avoid bruxism; and to favor the action of the external pterygoids and thus encourage the active push of the mandible.

For patients with a Class II malocclusion, the preorthodontic trainer appliance is constructed with the mandible in a lightly protruded position, similar to the therapeutic position used in activator treatment. For oral screen treatment, Graber³⁰ indicated that the construction bite cannot be as protrusive as that with an activator, and a screen is of value mainly in cases of mild Class II malocclusions. Similarly, we thought that myofunctional appliances might be a reliable alternative for sagittal activation of the mandible in the early mixed dentition period. A review of the literature presents no information on

whether the preorthodontic trainer appliance can actually improve a Class II skeletal relationship. Although the use of myofunctional appliances such as the oral screen in the primary and mixed dentitions are mentioned in the literature,^{8,31} only one study has been published concerning the specific alterations induced by these procedures in the early occlusal developmental stages.²² One study has been published concerning the trainer appliances combined with the straight wire system.³²

At the end of the study period, the myofunctional trainer group subjects showed anterior rotation and sagittal growth of the mandible, increases in SNB, facial height, and lower incisor proclination, reductions of ANB and overjet, and retroclination of upper incisors. However, only total facial height increase, lower incisor proclination, and overjet reduction were statistically significantly different when compared with the changes in the control group. This implies that the skeletal changes were not significant enough to be distinguished from normal growth, and the reduction of overjet was mainly related to the lower incisor proclination. These results are in accordance with the works of Tallgren et al⁸ and Owman-Moll and Ingervall,³¹ who reported similar changes with the use of another type of myofunctional appliance (oral shields).

CONCLUSIONS

At the end of the study period, in the trainer group, only the total facial height increase, lower incisor proclination, and overjet reduction were significantly higher compared with the changes observed in the control group. This study demonstrates that preorthodontic trainer application induces basically dentoalveolar changes that result in a significant reduction of overjet and can be used with appropriate patient selection.

REFERENCES

- Walpole Day AJ, Trotter PA, Norris N. A modified oral screen made of latex. *Br Dent J.* 1949;87:143–147.
- Kurer J. Improved oral screen. *Int Dent J.* 1952;3:225–226.
- Taylor AT. The use of oral screens with fixed appliances. *Int Dent J.* 1952;3:232–234.
- Massler M. The oral screen. *J Dent Child.* 1952;19:100–106.
- Kraus F. Vestibular and oral screens. *Trans Eur Orthod Soc.* 1956;32:217–224.
- Toepfer AK, Massler M, Brown WAB. Effectiveness of the oral screen in the treatment of upper incisor protrusions. *Am J Orthod.* 1959;45:759–767.
- Townend BR. The mouth screen. *Br Dent J.* 1960;108:20–22.
- Tallgren A, Christiansen R, Ash MM, Miller RL. Effects of a myofunctional appliance on orofacial muscle activity and structures. *Angle Orthod.* 1998;3:249–258.
- McNamara JA. Components of Class II malocclusion in children 8–10 years of age. *Angle Orthod.* 1981;51:177–202.
- Charlier JP, Petrovic A, Herrman-Stutzmann J. Effects of mandibular hyperpropulsion on the prechondroblastic zone of young rat condyle. *Am J Orthod.* 1969;55:71–74.
- Stockli PW, Willert HG. Tissue reactions in the temporo-mandibular joint resulting from anterior displacement of the mandible in the monkey. *Am J Orthod.* 1971;60:142–155.
- McNamara JA. Neuromuscular and skeletal adaptations to altered function in the orofacial region. *Am J Orthod.* 1973;64:578–606.
- Basciftci FA, Uysal T, Büyükerkmen A, Sari Z. The effects of activator treatment on the craniofacial structure of Class II division 1 patients. *Eur J Orthod.* 2003;25:87–93.
- Sari Z, Göyenc Y, Doruk EC, Usumez S. Comparative evaluation of a new removable jasper jumper functional appliance versus an activator—headgear combination. *Angle Orthod.* 2003;73:286–293.
- Andresen V, Haupt K. *Funktionsorthopädie. Die Grundlagen des Norwegischen Systems.* Leipzig, Germany: Johann Ambrosium Barth; 1945.
- Bergersen EO. Preventive eruption guidance in the 5 to 7 year old. *J Clin Orthod.* 1995;29:382–395.
- Tulloch JF, Medland W, Tuncay OC. Methods use to evaluate growth modification in class II malocclusion [review]. *Am J Orthod Dentofacial Orthop.* 1990;98:340–347.
- Woodside DG, Linder-Aronson S, Lundström A, McWilliam J. Mandibular and maxillary growth after changed mode of breathing. *Am J Orthod Dentofacial Orthop.* 1991;100:1–18.
- Linder-Aronson S, Woodside DG, Hellsing E, Emerson W. Normalization of incisor position after adenoidectomy. *Am J Orthod Dentofacial Orthop.* 1993;103:412–427.
- Quadrelli C, Ghiglione V, Marchetti C. Relationships between posture, dysfunctions of the soft tissues of the stomatognathic apparatus, respiration and occlusion in early treatment of skeletal Class II. Paper presented at: Congress “Occlusion and Posture; New Trends and New Problems”; June 2001; Milan, Italy.
- Quadrelli C, Ghiglione V, Gheorghiu M. Relationships between posture, dysfunction of soft tissues of the stomatognathic apparatus, respiration and occlusion in the early treatment of skeletal Class II. Paper presented at: XVI National Congress Sido; October 26–27, 2001; Genoa, Italy.
- Quadrelli C, Gheorghiu M, Marchetti C, Ghiglione V. Approccio miofunzionale precoce nelle II Classi scheletriche. *Mondo Ortod.* 2002;2:109–121.
- Owen AH. Morphologic changes in the transverse dimension using the Frankel appliance. *Am J Orthod Dentofacial Orthop.* 1983;83:200–217.
- Gibbs SL, Hunt NP. Functional appliances and arch width. *Br J Orthod.* 1992;19:117–125.
- Ung N, Koenig J, Shapiro PA, Shapiro G, Trask G. A quantitative assessment of respiratory patterns and their effects on dentofacial development. *Am J Orthod Dentofacial Orthop.* 1990;98:523–532.
- Houston WBJ. The analysis of errors in orthodontic measurements. *Am J Orthod.* 1983;83:382–390.
- Dermaut LR, van den Eynde F, de Pauw G. Skeletal and dentoalveolar changes as a result of headgear activator therapy related to different vertical growth patterns. *Eur J Orthod.* 1992;14:140–146.
- Cura N, Saraç M, Öztürk Y, Sürmeli N. Orthodontic and orthopedic effects of activator; activator-HG combination and Bass appliance: a comparative study. *Am J Orthod Dentofacial Orthop.* 1996;110:36–45.
- Ruf S, Baltromejus S, Pancherz H. Effective condylar growth and chin position changes in activator treatment: a cephalometric roentgenographic study. *Angle Orthod.* 2001;71:4–11.
- Graber TM. The use of muscle forces by simple orthodontic appliances. *Am J Orthod.* 1979;76:1–20.
- Owman-Moll P, Ingervall B. Effect of oral screen treatment on dentition, lip morphology, and function in children with incompetent lips. *Am J Orthod.* 1984;85:37–46.
- Mahony D. Combining functional appliances in the straightwire system. *J Clin Pediatr Dent.* 2002;26:137–140.